

Clinical Commentary

Lower dopamine transporter density in an asymptomatic patient with Kleine-Levin syndrome

Hoexter MQ, Shih MC, Mendes DD, Godeiro-Junior C, Felicio AC, Fu YK, Tufik S, Bressan RA. Lower dopamine transporter density in an asymptomatic patient with Kleine-Levin syndrome. *Acta Neurol Scand* 2008; 117: 370–373.
© 2007 The Authors Journal compilation © 2007 Blackwell Munksgaard.

Background – Kleine-Levin syndrome (KLS) is a rare disorder whose pathophysiological mechanisms remain unknown. **Patients and methods** – To investigate dopamine abnormalities in KLS, a [^{99m}Tc] – TRODAT-1 single photon emission computerized tomography (SPECT) was performed in a patient with KLS during the asymptomatic period and compared with three matched healthy controls. **Results** – The patient had 14% lower striatal dopamine transporter binding potential (DAT-BP) compared to the mean DAT-BP of three healthy controls. **Conclusion** – This study provides *in vivo* evidence for abnormalities in the DAT-BP, suggesting an involvement of the dopaminergic system in the pathophysiology of KLS.

**M. Q. Hoexter^{1,2}, M. C. Shih^{1,2},
D. D. Mendes², C. Godeiro-Junior³,
A. C. Felicio^{1,3}, Y. K. Fu⁴, S. Tufik⁵,
R. A. Bressan^{1,2}**

¹LiNC–Laboratório Interdisciplinar de Neurociências Clínicas, Universidade Federal de São Paulo, São Paulo, Brazil; ²Department of Psychiatry, Universidade Federal de São Paulo, São Paulo, Brazil; ³Department of Neurology, Universidade Federal de São Paulo, São Paulo, Brazil; ⁴INER–Institute of Nuclear Energy Research–Taiwan, Long-Tan, Taiwan; ⁵Department of Psychobiology, Universidade Federal de São Paulo, São Paulo, Brazil

Key words: dopamine transporter; Kleine-Levin syndrome; single photon emission computed tomography; striatum; TRODAT-1

Marcelo Q. Hoexter and Rodrigo A. Bressan, LiNC–Laboratório de Neurociências Clínicas, Department of Psychiatry, Universidade Federal de São Paulo. Rua Dr Bacelar, 334, Postal Code 04026-001. São Paulo-SP, Brazil
Tel.: +55(11) 5084 7060
Fax: +55(11) 5084 7061
e-mail: mqhoexter@psiquiatria.epm.br; r.bressan@iop.kcl.ac.uk

Accepted for publication September 5, 2007

Introduction

Kleine-Levin syndrome (KLS) is a rare neuropsychological disorder characterized by intermittent periods of hypersomnia, compulsive hyperphagia, hypersexuality and other behavioral and cognitive disturbances such as irritability, depression, euphoria, difficulty concentrating, social disinhibition, incoherent speech, aggressiveness, delusions, derealization, and hallucinations (1). This syndrome is likely to be underdiagnosed and misinterpreted as other neurological or psychiatric disorder (schizophrenia, conversion disorder, mood disorder, or a consequence of substance abuse) (2).

The exact etiology and pathogenesis mechanisms of KLS remain unknown and the diagnosis

in its first episode is difficult due to the lack of objective tests. Abnormalities in dopaminergic tone (3) and neurotransmitter imbalance in the serotonergic and dopaminergic pathways have been proposed (4). Both dopamine and serotonin are known major regulators of several physiologic functions, including locomotion control, cognition, affect, and neuroendocrine hormone secretion (5).

The purpose of this case report was to investigate *in vivo* dopamine neuronal abnormalities in a patient with KLS compared to three healthy controls (HC) matched for gender, age, and years of education using a dopamine transporter (DAT) radiotracer and single photon emission computerized tomography (SPECT).

Case report

A 17-year-old male patient was admitted to our hospital with a 1-week history of abrupt behavioral changes characterized by hypersomnolence, confusion, disorientation, irritability, incoherent speech, difficulty concentrating, poor personal care, and indirect signs of sensorimotor alterations. The patient spent most of the night and day asleep, waking up spontaneously to eat or to impulsively try to have sex. He had binges in which he could eat anything he could reach, from several chocolate bars in a supermarket to a gum thrown in the garbage. His family described him as sleepy, irritable, apathetic, and thought-disordered. Before lying down on the floor and falling asleep in the emergency room, our patient continuously switched lights on and off, stripped down wallpapers and occasionally made sexual advances to hospital staff. He was very inattentive and could say no more than a few words or express himself properly. If he was awakened or prevented from sleep, he would become very irritable and uncooperative.

This episode was preceded by a viral infection (fever, headache, and throat pain) and he had no previous history of psychiatry or medical problems, such as epilepsy, brain injury, or substance abuse. He had no family history of psychiatric disorders either. He was born after a normal pregnancy and his psychomotor development was adequate.

Clinical and neurological examinations (signs of focal lesion or meningitis) as well as laboratory tests (blood count, blood biochemistry, renal, liver and thyroid function and urinalyses), head computed tomography (CT), cerebrospinal fluid, and electroencephalogram were normal. Risperidon (1 mg/day) was given based on the hypothesis of first psychotic episode.

As there was no symptomatic improvement, the patient came back to our hospital for a new evaluation. In this visit, the diagnosis of KLS was raised because of his persistent somnolence, behavioral and cognitive disturbances, compulsive eating, and hypersexuality. Risperidone was discontinued and lithium carbonate (600 mg/day) was prescribed with symptom remission within 2 weeks. Two months after this first episode, the patient had a relapse with similar symptoms but much less intense, which lasted 10 days. He met the American Academy of Sleep Medicine criteria for KLS (1). After this episode, symptoms subsided and lithium therapy was discontinued 4 months later without further relapses in the 15-month follow-up. The patient had retrograde amnesia of the episodes.

To evaluate dopaminergic and sleep disorders a SPECT scan and a polysomnography were performed two and a half months after lithium discontinuation and with the patient asymptomatic.

Methods

Subjects

The diagnosis of KLS was made according to the American Academy of Sleep Medicine criteria (1). Three HC were matched with the KLS patient for gender (male), age (18 years old) and level of education (high school completed). This study was approved by the Ethics Committee at the Universidade Federal de São Paulo.

Polysomnography

Polysomnography was recorded using a 32-channel equipment (SonolabTM MeditronTM, Sao Paulo, Brazil), resolution 256 Hz: 22 EEG leads, two electrooculogram, one chin electromyogram, one leg electromyogram, one electrocardiogram, one tracheal microphone, one oronasal thermistor, two chest and abdominal effort sensors, and one pulse oximeter (NellcorTM; Pleasanton, CA, USA). Sleep stages were scored visually using Rechtschaffen and Kales criteria.

Imaging procedures and analysis

SPECT scans were performed with [^{99m}Tc]-TRODAT-1, a radiotracer with high selectivity and specificity for DAT. TRODAT-1 kits were produced by the Institute of Nuclear Energy Research (INER-Taiwan, Taiwan). Images were acquired 4 h after the injection of 814 MBq (± 74) of [^{99m}Tc]-TRODAT-1 using a double-headed gamma camera Hawk-Eye (General Electric Medical System, Milwaukee, WI, USA). DAT density was calculated with BP using regions of interest (ROI) bilaterally drawn in the striatum (STR) and in the occipital cortex (OCC) as background. BP was calculated using the formula: $[(STR - OCC)/OCC]$.

Results

Polysomnography was essentially normal except for a short reduction in the rapid eye movement (REM) percentage (18.7%). Total sleep time was 395.5 min with a sleep efficacy of 85.9%. Sleep and REM latency were 7.6 and 62.5 min, respectively. The percentage of non-REM stages was 5.1% for

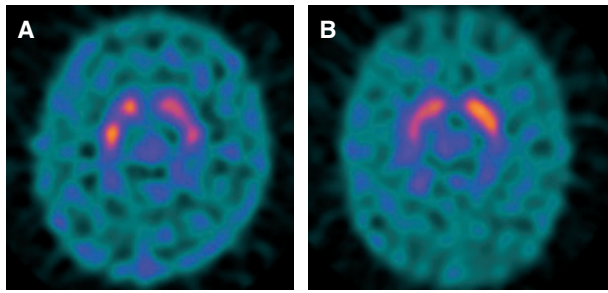


Figure 1. Representative [^{99m}Tc]-TRODAT-1 SPECT striatal images in the patient with Klein-Levin syndrome (A) and in a healthy control subject (B).

Table 1 Striatal DAT-BP of a patient with KLS and controls

	DAT-BP		
	Striatal DAT-BP (left)	Striatal DAT-BP (right)	Striatal DAT-BP (mean)
KLS	1.17	1.14	1.15
Controls ($n = 3$) (mean \pm SD)	1.37 \pm 0.06	1.32 \pm 0.01	1.34 \pm 0.03

DAT-BP, dopamine transporter binding potential; KLS, Kleine-Levin syndrome. Difference between DAT-BP (KLS) and DAT-BP (controls): 14%.

stage 1, 48.8% for stage 2, 6.6% for stage 3, and 20.9% for stage 4. Mean SaO_2 was 95.5%, apnea-hypopnea index was 3.7/h and no periodic limb movements were seen.

The KLS patient showed 14% lower striatal DAT-BP compared to matched controls (Fig. 1). Individual striatal DAT-BP is summarized in Table 1.

Discussion

This case shows reduced striatal DAT density in the asymptomatic period without polysomnographic changes. Neuropathological case reports showing inflammatory signs of encephalitis in KLS patients, such as hypopigmentation of substantia nigra (4), could contribute to structural degeneration resulting in dopamine neuron loss and consequent decrease in DAT receptors, though morphometric imaging evidence is missing in the literature. Moreover, decreased DAT could be a result of a downregulation of these transporters to compensate lower dopamine availability in the synaptic cleft as a consequence of reduced dopaminergic tone observed in KLS (3). Finally, higher cerebrospinal fluid levels of homovanillic acid, a dopamine metabolite, seen in the symptomatic and even in the asymptomatic periods of this syndrome (6), would lead to lower levels of DAT receptors in an attempt to balance increased dopamine turn-

over. Dauvilliers et al. (7) did not find any allele or genotype association between catechol-*O*-methyltransferase and KLS that could contribute to this hypothesis, suggesting that other mechanisms may be involved in these dopamine changes.

The finding of decreased DAT in the asymptomatic period of this disorder is in line with recent studies showing that KLS is not a benign disorder as previously considered and is associated with persistent brain dysfunction, particularly seen in neuropsychological tests (8–10) and functional neuroimaging studies (9–11). Landtblom et al. (10) investigated cases with classical KLS during remission and reported short-term memory dysfunction in all four cases as well as a hypoperfusion of the temporal lobes and frontotemporal region in two cases on SPECT examination. A recent cerebral blood flow SPECT study demonstrated hypoperfusion of several brain regions during symptomatic periods, including basal ganglia, and these changes persisted even in the asymptomatic phase of this syndrome. The longer this syndrome course, the more extensive the hypoperfusion regions during the asymptomatic period (11), suggesting long-lasting cerebral dysfunction.

This is the first report of lower striatal DAT density in an asymptomatic KLS patient, suggesting dopamine system dysfunction in this syndrome. Further studies during KLS exacerbation will provide useful information on the timing of dopaminergic dysfunction of this rare disorder.

Conflicts of interest

None.

References

1. AMERICAN ACADEMY OF SLEEP MEDICINE. The International Classification of Sleep Disorders – Revised. Chicago, IL: Hauri P Ed, 2005.
2. ORLOSKY MJ. The Kleine-Levin syndrome: a review. *Psychosomatics* 1982;**23**:609–21.
3. CHESSON AL JR, LEVINE SN, KONG LS, LEE SC. Neuroendocrine evaluation in Kleine-Levin syndrome: evidence of reduced dopaminergic tone during periods of hypersomnolence. *Sleep* 1991;**14**:226–32.
4. KOERBER RK, TORKELSON R, HAVEN G, DONALDSON J, COHEN SM, CASE M. Increased cerebrospinal fluid 5-hydroxytryptamine and 5-hydroxyindoleacetic acid in Kleine-Levin syndrome. *Neurology* 1984;**34**:1597–600.
5. AMARA SG, KUJAR MJ. Neurotransmitter transporters: recent progress. *Annu Rev Neurosci* 1993;**16**:73–93.
6. LIVREA P, PUCA F, BARNABA A, DI REDA L. Abnormal central monoamine metabolism in humans with ‘true hypersomnia’ and ‘subawkefulness’. *Eur Neurol* 1977;**15**:71–6.
7. DAUVILLIERS Y, MAYER G, LECENDREUX M et al. Kleine-Levin syndrome: an autoimmune hypothesis based on clinical and genetic analyses. *Neurology* 2002;**59**:1739–45.

Lower DAT density in a Kleine-Levin patient

8. FONTENELLE LF, MENDLOWICZ MV, MARQUES C, MATTOS P, VERSIANI M. Persistent neuropsychological deficits in the Kleine-Levin syndrome. *Acta Neural Scand* 2003;**107**:304–5.
9. LANDTBLOM AM, DIGE N, SCHWERDT K, SAFSTROM P, GRANERUS G. Short-term memory dysfunction in Kleine-Levin syndrome. *Acta Neurol Scand* 2003;**108**:363–7.
10. LANDTBLOM AM, DIGE N, SCHWERDT K, SAFSTROM P, GRANERUS G. A case of Kleine-Levin syndrome examined with SPECT and neuropsychological testing. *Acta Neurol Scand* 2002;**105**:318–21.
11. HUANG YS, GUILLEMINAULT C, KAO PF, LIU FY. SPECT findings in the Kleine-Levin syndrome. *Sleep* 2005;**28**:955–60.